

EUROPEAN JOURNAL OF CARDIO-THORACIC SURGERY

The helical ventricular myocardial band: global, three-dimensional, functional architecture of the ventricular myocardium

Mladen J. Kocica, Antonio F. Corno, Francesc Carreras-Costa, Manel Ballester-Rodes, Mark C. Moghbel, Clotario N.C. Cueva, Vesna Lackovic, Vladimir I. Kanjuh and Francisco Torrent-Guasp

Eur J Cardiothorac Surg 2006;29:21-40

DOI: 10.1016/j.ejcts.2006.03.011

This information is current as of July 28, 2009

The online version of this article, along with updated information and services, is located on the World Wide Web at:

http://ejcts.ctsnetjournals.org/cgi/content/full/29/Suppl_1/S21

The European Journal of Cardio-thoracic Surgery is the official Journal of the European Association for Cardio-thoracic Surgery and the European Society of Thoracic Surgeons. Copyright © 2006 by European Association for Cardio-Thoracic Surgery. Published by Elsevier. All rights reserved. Print ISSN: 1010-7940.

Review

The helical ventricular myocardial band: global, three-dimensional, functional architecture of the ventricular myocardium[☆]

Mladen J. Kocica^{a,*}, Antonio F. Corno^b, Francesc Carreras-Costa^c,
Manel Ballester-Rodes^d, Mark C. Moghbel^e, Clotario N.C. Cueva^f,
Vesna Lackovic^g, Vladimir I. Kanjuh^h, Francisco Torrent-Guasp^{i,✱}

^a Clinic for Cardiac Surgery, Institute for Cardiovascular Diseases, UC Clinical Centre of Serbia,
8th Kosta Todorovic St., 11000 Belgrade, Serbia and Montenegro

^b Alder Hey Royal Children Hospital, Liverpool, United Kingdom

^c Department of Cardiology, Cardiac Imaging Unit, Hospital Sant Pau, Barcelona, Spain

^d Department of Medicine, Faculty of Medicine, University of Lleida, Lleida, Spain

^e Department of Anatomical Sciences UC Dundee, Dundee, Scotland, United Kingdom

^f Department of Cardiac Surgery, UC Federal de Bahia, Salvador, Brazil

^g Institute for Histology and Embriology, Medical School UC Belgrade, Belgrade, Serbia and Montenegro

^h Serbian Academy for Sciences and Arts, Belgrade, Serbia and Montenegro

ⁱ Denia, Alicante, Spain

Received 23 February 2006; accepted 2 March 2006

To our beloved friend and teacher, Francisco Torrent-Guasp (1931–2005).

Summary

We are currently witnessing the advent of new diagnostic tools and therapies for heart diseases, but, without serious scientific consensus on fundamental questions about normal and diseased heart structure and function. During the last decade, three successive, international, multidisciplinary symposia were organized in order to setup fundamental research principles, which would allow us to make a significant step forward in understanding heart structure and function. Helical ventricular myocardial band of Torrent-Guasp is the revolutionary new concept in understanding global, three-dimensional, functional architecture of the ventricular myocardium. This concept defines the principal, cumulative vectors, integrating the tissue architecture (i.e. form) and net forces developed (i.e. function) within the ventricular mass. Here we expose the compendium of Torrent-Guasp's half-century long functional anatomical investigations in the light of ongoing efforts to define the integrative approach, which would lead to new understanding of the ventricular form and function by linking across multiple scales of biological organization, as defined in ongoing Physiome project. Helical ventricular myocardial band of Torrent-Guasp may also, hopefully, allow overcoming some difficulties encountered in contemporary efforts to create a comprehensive mathematical model of the heart.

© 2006 Elsevier B.V. All rights reserved.

Keywords: Ventricle; Anatomy; Myocardium; Physiology; Helical ventricular myocardial band

'Great spirits have always encountered opposition from mediocre minds. The mediocre mind is incapable of understanding the man who refuses to bow blindly to conventional prejudices and chooses instead to express his opinions courageously and honestly.' Albert Einstein, quoted in *New York Times*, March 13, 1940.

1. Introduction

Ever since Danish anatomist, Nicolaus Steno (Niels Stensen, 1638–1686), settled the muscular nature of the heart, in 1663 [1], the architecture of the ventricular myocardium became a fascination for the generations of investigators. In addition to many other features, almost all historical predecessors in the field (Fig. 1), from Richard Lower (1631–1691) onward, have recognized helical, transmural, overlapping pattern of the ventricular myocardial fibers [2–21]. Unresolved problem was to reveal unique, rule-based assignment which, as Franklin Paine Mall (1862–1917) urged, 'may be applied equally well to all the

[☆] This article was presented on 28 May, 2005 at The New Concepts of Cardiac Anatomy and Physiology, Liverpool, United Kingdom.

^{*} Corresponding author. Tel.: +381 11 3670 609; fax: +381 11 3610 880.

E-mail address: kocica@sezampro.yu (M.J. Kocica).

URL: <http://www.ctsnet.org/home/mkocica>

[✱] Deceased.

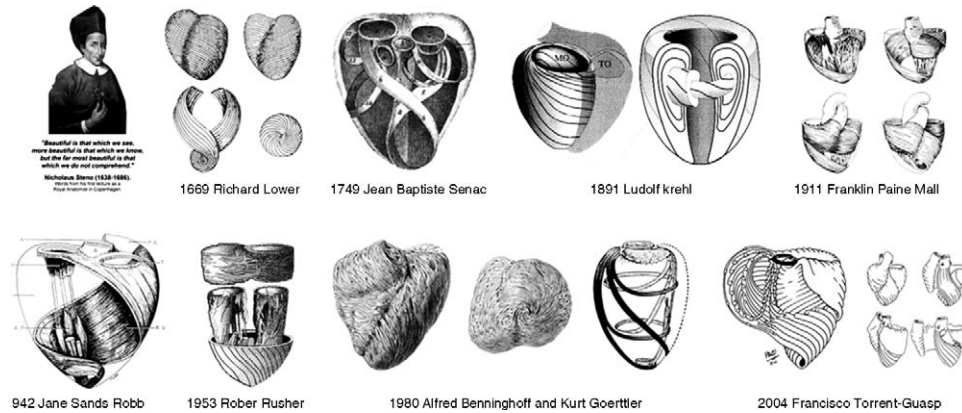


Fig. 1. Illustrated historical timetable of the mayor contributions in understanding the ventricular myocardial architecture.

ventricular myocardial fibers, showing them joined together in a coherent, common general architectural plan' [20]. This task was considered as the ultimate missing link between the ventricular form and function. But, since it was 'easy to observe and difficult to comprehend', as claimed James Bell Pettigrew (1834–1908), the global arrangement of ventricular myocardial fibers remained the 'Gordian Knot' of heart anatomy for almost five centuries [21].

Indeed, ventricular myocardium has proven remarkably resistant to macroscopic analyses of functional anatomy. Pronounced and practically indefinite global and local structural anisotropy of its fibers and other ventricular wall constituents produces electrical and mechanical properties that are nonlinear, anisotropic, time varying, and spatially inhomogeneous [3–12,22,23].

Spanish scientist, Francisco (Paco) Torrent-Guasp (1931–2005) has invested half century of his life in painstaking and meticulous research, before he was able to dissect the heart in a manner that unraveled this 'Gordian Knot' [Appendix 1–Francisco Torrent-Guasp's bibliography]. Helical ventricular myocardial band (HVMB) of Torrent-Guasp is a new concept, which provides important and firm ground for reconciliation of some exceeded concepts in cardiovascular medicine. This concept is dazzling due to its unique

intrinsic ingenuity and thus appears 'exceedingly simple in principle but wonderfully complicated in detail' [21].

We live in the era of substantial progress in understanding myocardial structure and function at the genetic, molecular and microscopic levels (Fig. 2). This rapid accumulation of knowledge has imposed a paradigm shift, necessitating integration and linking across multiple scales of biological organization – from proteins to cells, tissues, organs and organ systems – in order to understand a complexity of interactions between form and function, generating a specific behavior (normal or abnormal) in the biological system [22–25]. Accordingly, the global three-dimensional model of the ventricular myocardial mass, as HVMB, not only provides a common architectural plan of the ventricular myocardial fibers but also explains and tests its integrative capacity with other levels of biological organization, thereby unifying ventricular form and function as described in ongoing 'Physiome project' [24,25].

The primary purpose of this article is to (re)expose the anatomical background of HVMB concept, along with an attempt to clarify certain aspects that kindle disagreements [7,12,17,18,26,27]. Other anatomical descriptions of the HVMB appear in the literature ([2,3,5,6,13,15,16, Appendix 1]) and online at <http://www.torrent-guasp.com/>.

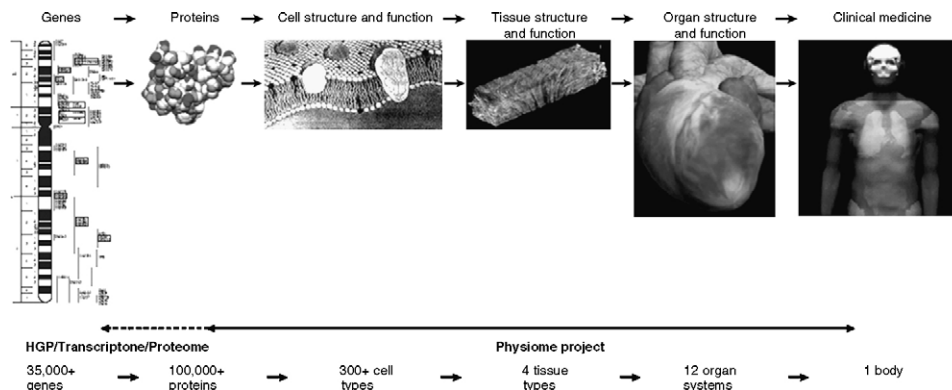


Fig. 2. Linking molecular and cellular events with physiological function must deal with wide ranges of length scales and timescales. Levels of biological organization from genes to proteins, cells, tissues, organs and finally the whole organism. The range of spatial scales – from 1 nm for proteins to 1 m for the whole body – requires a hierarchy of models. Different types of model are appropriate to each level, and relationships must be established between models at one level and the more detailed, but spatially or temporally limited, models at the level below. (Modified and reproduced with kind permission from Peter J. Hunter, The University of Auckland, Bioengineering Institute, Ref. [24].)

2. Helical ventricular myocardial band of Torrent-Guasp—anatomical compendium

'Follow the argument, wherever it leads.' *The Apology of Socrates. Plato (427 BC–327 BC).*

Trying to reach the endocardial surface or even to enter the ventricular cavity from any, arbitrary chosen, ventricular free-wall epicardial point, the path which offers the least resistance coincide with the natural, helical, overlapping course of the myocardial fibers (Fig. 3).

At this point, it is important to emphasize that since there is not any 'natural entrance' into the ventricular wall, a controlled incision (or blunt disruption) of the subepicardial fibers is the inevitable 'first step' in this experiment. This fact depicts that intact ventricles are naturally well coupled, both anatomically and functionally, so that 'two hearts can beat as one' [28]. Accordingly, the arbitrary 'cleavage plan', produced in this manner, does not disjoin and expose any distinctive anatomical structure, as some researches persistently want to believe [7,12,17,18]. Instead it is initiated by intentional blunt 'intrusion' into the ventricular mass [2,3,6,13,15,16] and subsequently guided by the 'principal fiber direction at given point, to accommodate factual difficulties arising from highly complex and anisotropic myocardial architectural design' [5]. Therefore, methodologically, Torrent-Guasp's blunt anatomical dissections, following predominant fiber directions, reveal their unique functional (i.e. vectorial) rather than a specific eclectic (i.e. discrete) anatomical planes within ventricular mass. Adopting this reproducible pathway, myocardial fiber fields were shown to course in a consistent and comparable organizational pattern within normal hearts of the same species [2,3,6,8,13,15,16].

To avoid semantic confusion, a clear definition of myocardial histology will be enumerated. Ventricular mass is a heterogeneous structure consisting of cardiac myocytes, connective tissue elements, blood vessels, nerves and interstitial fluid. First, ventricular myocardium is not considered to fulfill the biological criteria of a 'true syncytium'. Instead, it is considered to be a 'functional syncytium', composed of individual, morphologically discrete but functionally very well-coupled cells. This annotation might be useful for those who apply mathematics in biological systems, since it depicts that stochastic nature of

myocardial form and function on microscopic level becomes average and appears consistent with a continuous medium on macroscopic level [29]. The individual ventricular 'working' myocyte is elongated, branched, cylindrical cell with length that range from 50 to 150 μm and diameter ranging from 10 to 20 μm . Branching outer cell contours resembles the 'step-like facades of skyscrapers; the plateau of each step being occupied by an intercalated disc' [30]. Each ventricular myocardial cell is coupled by average of 11 neighbors, with 47% of the connections being of side-to-side (i.e. transverse) type and 53% of end-to-end (i.e. longitudinal) type [29–32]. The branching angle is usually acute so that tightly coupled adjacent cells run almost parallel with one another. Complex hierarchy of connective tissue (i.e. endomysium, perimysium and epimysium) provides a 'sponge-like' scaffold for complex hierarchy of myocardial cells, blood vessels and nerves. Thus, the groups of three or more myocytes surrounded by the perimysium could be distinguished as 'myocardial fibers,' and predominant local direction of their longitudinal axes defines the 'principal fiber direction' [7,18,33–36]. These fibers as well as their directions are clearly visible during the macroscopic analyses of the intact ventricles (after removal of fat tissue and epicardium). The Auckland group has demonstrated a higher, laminar level of the ventricular myocardial organization, providing additional evidence that the ventricular myocardium 'should not be viewed as a uniformly continuous structure' [8,25,37,38].

They have clearly shown that muscular fibers are arranged into distinct myocardial laminas, four to six myocytes thick, separated from adjacent laminas by the extracellular collagen network (Fig. 4A–C). The cardiac myocytes (fibers) are tightly coupled within the same, but sparsely coupled between the adjacent laminas. The planes of the laminas could be defined locally by the longitudinal axis of comprising myocardial fibers and by their spiral, branching transmural direction on the ventricular mass level (Fig. 4C–E) [8,25,37,38].

As observed by predecessors [4] and quantitatively demonstrated by Streeter in his histological sections through the ventricular free wall [5], myocardial fibers change their directions gradually from endocardium to epicardium. Subepicardial fibers are becoming subendocardial ones, after helical overlapping around the natural orifices. Fig. 5 demonstrates four fundamental anatomical facts, easily recognizable by pure inspection of the intact ventricles.




Fig. 3. Transversal section through the ventricular mass (bovine heart)—anterior (left) and upper (right) view. Asterisks (black) indicate the site of arbitrary linear sharp intrusion into the ventricular mass. Arrowhead (black) indicates the natural, helical, overlapping course of the myocardial fibers during their epicardial to endocardial transition. RV, right ventricle; LV, left ventricle; apm, anterior papillary muscle; ppm, posterior papillary muscle.

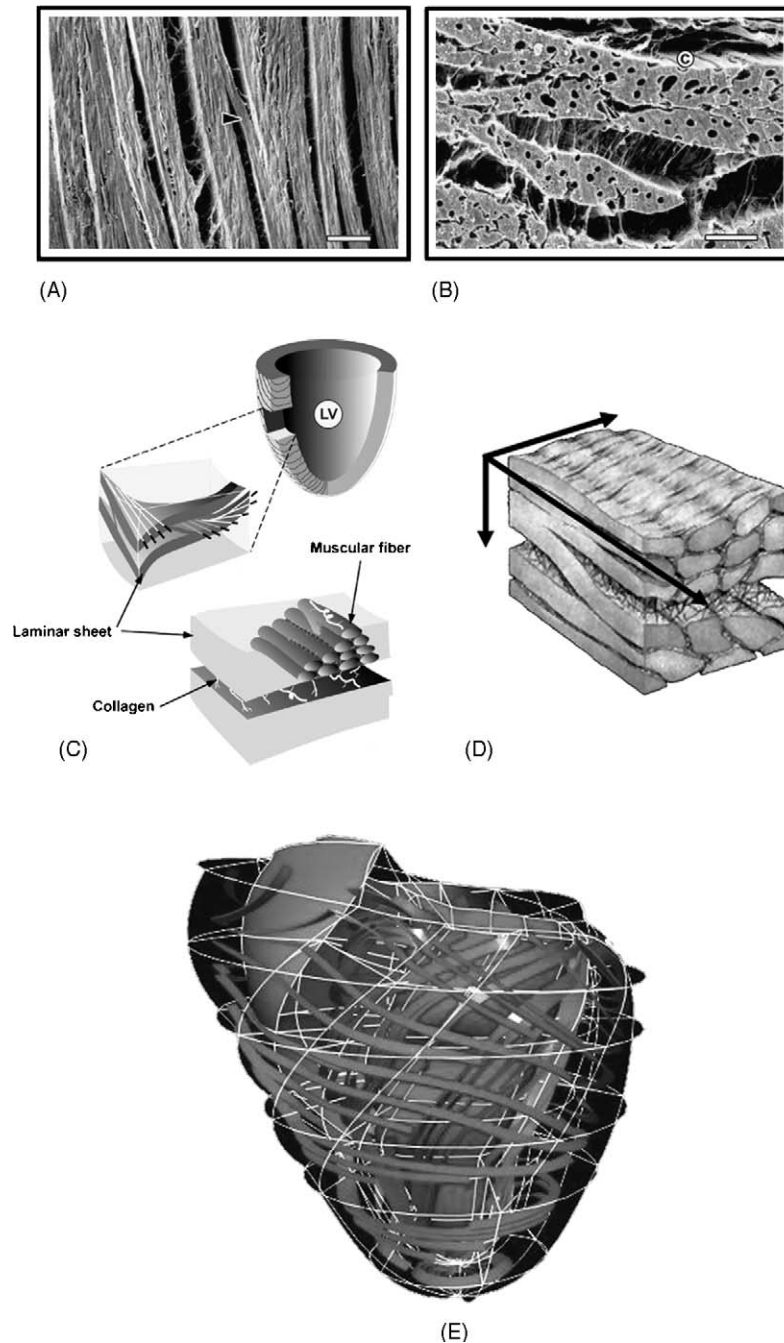


Fig. 4. The Auckland 'laminar sheet' model of the ventricular mass microstructure. (A) Micrograph of tangential surface of specimen showing layered organization of myocytes, branching of layers (arrow), and collagen fibers between adjacent sheets. Scale bar, 100 μm . (B) Micrograph of transverse surface of specimen. Perimysial connective tissue weave surrounding myocardial sheets is evident and covers surface capillaries (C). Scale bar, 0.25 μm . (C) Schematic of cardiac microstructure. Tissue block contains layers of tightly coupled myocytes—laminar sheets. The cardiac myocytes (fibers) are tightly coupled within the same, but sparsely coupled between the adjacent laminas. The planes of the laminas could be defined locally by the longitudinal axis of comprising myocardial fibers and by their spiral, branching transmural direction on the ventricular mass level. (D) Orientations of the principal muscle fiber axes (i.e. tissue vectors) are indicated. (E) Rectangular tubes track along the fiber direction with the major flat dimension lying in the sheet plane. ((A–D) Modified and reproduced with kind permission from Ref. [8], © The American Physiological Society, 1995; (E) reproduced with kind permission from Ian LeGrice and Peter J. Hunter, The University of Auckland, Bioengineering Institute.)

Some of the most superficial fibers are removed, by gentle peeling off along their principal direction, to make these facts even more obvious.

The first observation is that the apex of the heart belongs to the left ventricle (LV). Apical LV orifice (easily palpable during cardiac surgery) is normally very small and virtual one,

covered with endo- and epicardium only. It may become a clinical problem in ischemic and dilated ventricles, when its size increases due to spherical remodelling [13]. The apical orifice becomes more evident following removal of apical superficial fibers (Fig. 5B). The continuity of subepicardial and subendocardial fibers, after helical overlapping around a

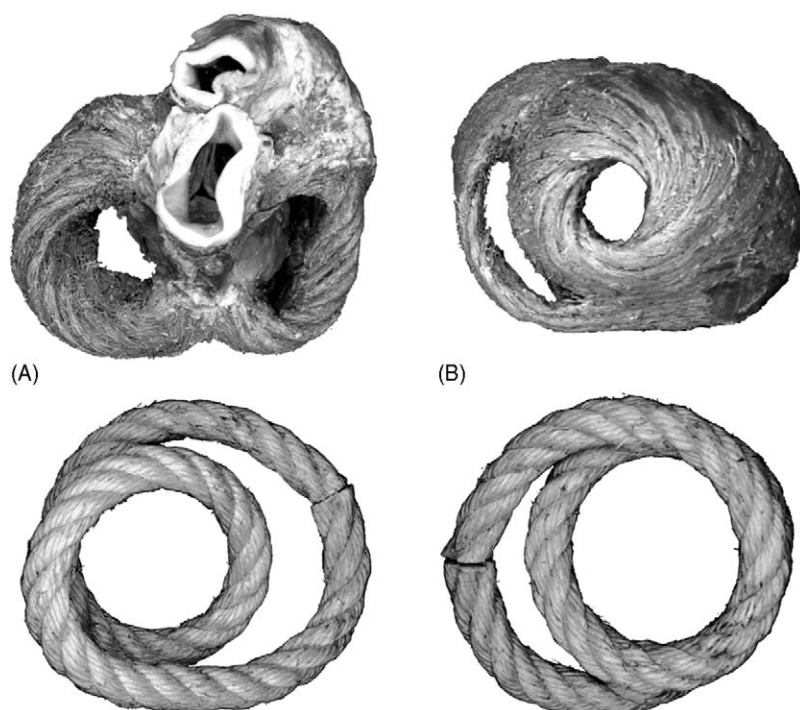


Fig. 5. Upper tray: helical overlapping path of subepicardial fibers at basal (A) and apical (B) regions of the bovine ventricles. The epicardium and some of the most superficial fibers are removed, by gentle peeling-off along their principal direction. Lower tray: two-dimensional helical rope model mimicking the fiber path at the ventricular base (A) and apex (B).

central tunnel, was recognized as 'vortex cordis' by Lower in the 17th century [19].

Second, the LV base (i.e. the mitral orifice) also demonstrates a helical overlapping path during the continuous outside–inside transition of the LV free-wall myocardial fibers. To make this more obvious, an alternate group of fibers (Fig. 5A) was removed to expose the grooves defined by the intact adjacent fibers. The majority of fibers pass without insertion to 'the mitral fibrous annulus', a structure that practically does not exist in the posterior leaflet area or may appear as a discontinuous tiny fibrous structure.

Third, the crescent orifice appears after dissecting the alternate groups of fibers belonging to the linear apical border of the right ventricular (RV) free wall. This shows helical overlapping path of the subepicardial fibers during their continuous transition to the subendocardial ones (Fig. 5B).

Forth, and finally, a helical overlapping and continuous epicardial to endocardial transition could be easily observed following dissection of the RV free-wall myocardial fiber arrangement around the orifice at RV base (i.e. tricuspid orifice) (Fig. 5A).

Previously described anatomical dissections show many similarities but also define significant differences between the basal and the apical regions. The fibers belonging to these distinctive regions follow a reciprocal helical course from epicardium to the endocardium as shown in Fig. 6.

A simple rope model creates an elegant way to demonstrate this configuration, as well as many other relationships within the architecture of the ventricular myocardium. The helical rope model (Figs. 5 and 6) also displays cross-sectional and two-dimensional relationships,

together with conveying anatomical reasons for different thicknesses of the LV and RV free walls. The LV free wall that is composed of two loops is thicker than the RV free wall, which is constituted by only one loop. The ventricular myocardium consists of a hierarchy of helical structures ('spirals within spiral'), with different length scales within the rope [20,23]. Finally, this model displays the continuum mechanics that could be efficiently applied toward discreteness [39]. The absence of visible branching connections between large rope bundles is the major weakness of this model, but such connections may realistically exist between the smaller filaments (i.e. myocardial fiber analogues) that comprise the individual large bundles.

The aforementioned four anatomical facts together with comparisons to the rope model imply existence of a secondary, 'helical rope-like' structure within ventricular myocardium. Using this hypothesis, the ventricular myocardium can be viewed as muscular band (i.e. stretched-out rope), that is twisted and curled in two helical loops, a concept that originates from the phylogenic and ontogenetic similarities between heart and blood vessels. Using this concept, the heart appears as pulsatile, linear or looped tubular organ (i.e. modified blood vessel), interposed between inflow and outflow blood vessels, either as the final product or in its intermediate form during embryogenesis. Specific differences in preferential three-dimensional myocyte orientation within developing ventricular mass are generated during the looping and overlapping of the heart tube with atrio-ventricular separation and septation at macroscopic level, as well during the events that result in filling up the cardiac jelly with different cells at microscopic level during trabeculation, compaction, interstitial, coron-

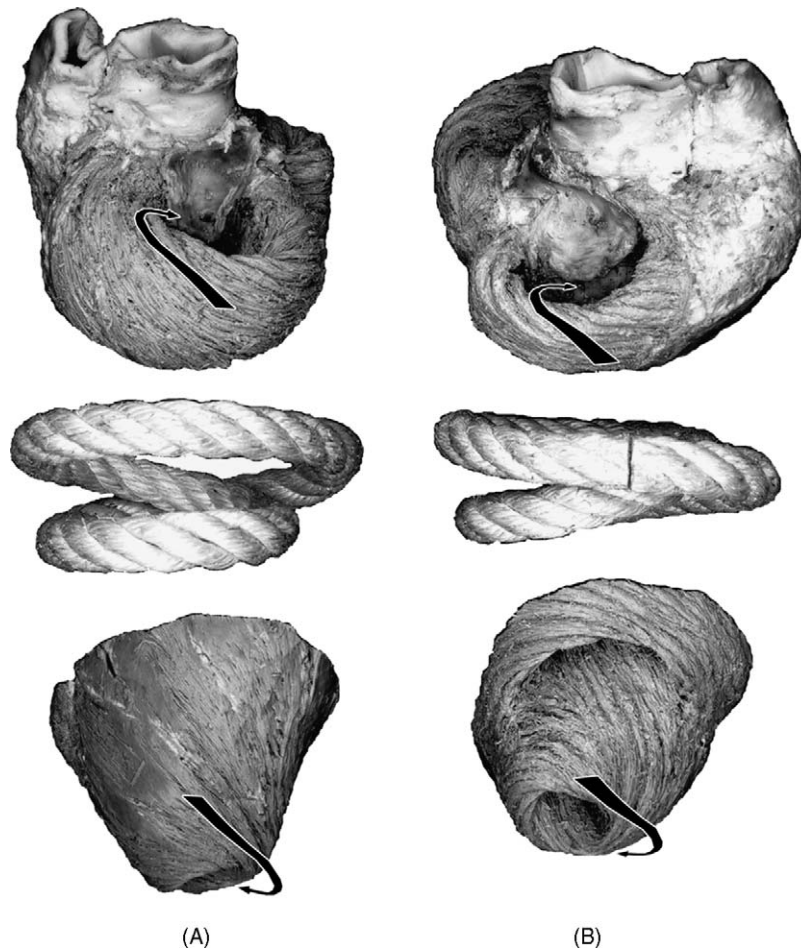


Fig. 6. The opposite directions (arrows) of helical overlapping fiber courses at the LV (A) and RV (B) basal and apical portions (bovine heart), with helical rope model depicting this difference.

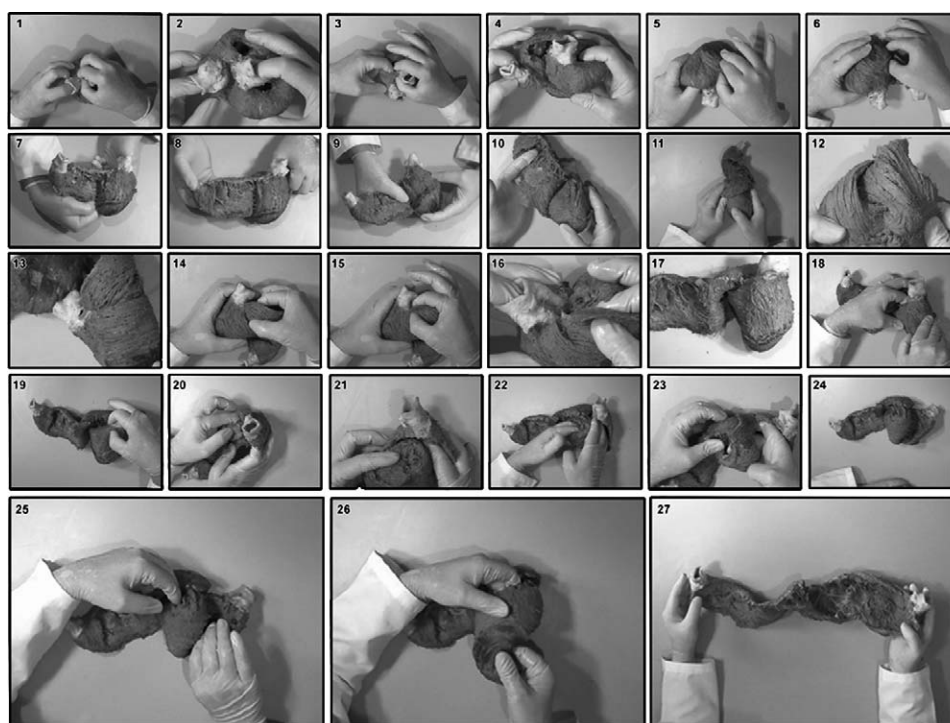
ary and conduction system development. These morphological adjustments, occurring at different time and length scales during the cardiogenesis, are genetically and epigenetically controlled. The final pattern, as the result of these rearrangements (i.e. the form), becomes a smooth and coordinated coupling of electrical activation, contraction and directional blood flow (i.e. the function) through the ventricles into pulmonary and systemic circulation [40–49].

If the heart is a modified blood vessel, then their similarity should be the greatest in the earliest cardiogenesis. In addition, the heart should be serially connected with true inflow and outflow blood vessels in order to maintain the blood flow and prevent its leakage outside developing cavities. All these facts are clearly recognizable during the earliest phases of normal cardiogenesis (i.e. the heart tube stadium) [40–42]. The heart tube as linear, segmented, hollow secondary structure, inevitably has its finite macroscopic (i.e. length, width, diameters, thickness, etc.) and microscopic characteristics (i.e. cellular and interstitial composition, arrangement).

It seems quite logical to expect that we could easily trace this secondary structure (i.e. the heart tube) within the final, three-dimensional architectural design of the mature organ, particularly because of blood flow and leakage-proof prerequisites. In reality, it is not so difficult to follow the

external transformations of the heart tube during its transition from linear to three-dimensional (tertiary) structure [40–42,45–49]. But, due to complex macroscopic and microscopic changes occurring inside the tertiary structure of developing ventricles, it is not realistic to expect that secondary structure would be accessible in a form of hollow tube but rather, as we noted above, in a form of continuous muscular band. This band, of course, is composed not only of myocytes but also of interstitial connective tissue and other nonmuscular elements. Likewise, this muscular band does not present any distinctive embryological or anatomical entity but reflects the unraveled helical path of muscular fibers encircling ventricular cavities. After atrial insulation, this path arranges to fit with spirally septated truncus arteriosus, allowing development and appropriate positioning of the pulmonary artery and the aorta in respect to the ventricular chambers. Thus, the great arteries indicate the beginning and the end of the underlying ventricular secondary structure [13,23,50].

Fig. 7 depicts successive steps of dissection technique applied in unraveling the ventricular mass into HVMB. After the separation of the pulmonary artery and the aorta (Fig. 7(1, 2)), some superficial fibers (i.e. aberrant fibers) bridging the anterior interventricular sulcus are incised in order to move aside the right ventricular (RV) free wall



Francisco Torrent-Guasp, Denia 2004

Fig. 7. Successive dissection stages, unraveling the ventricular mass (bovine heart) into HVMB of Torrent-Guasp. Detailed description of particular stages may be found in paragraphs describing the dissection technique (see also Video 2—available only in online version of this article).

(Fig. 7(3–7)). By doing so, we arrive to the posterior linear border of the RV cavity, which is represented by the linear bottom of the dihedral angle constituted by the RV free wall and the interventricular septum (Fig. 7(8)). The posterior linear border of the RV cavity has special importance, since it points out the only possible trajectory, which would allow further dissection of the HVMB. The beginning of this trajectory is exposed by pushing laterally RV free wall (Fig. 7(9)). Following the predominant fiber direction, we can easily see that this path encircles the LV, up to the root of the aorta (Fig. 7(10–14), Video 1—available only in online version of this article).

By cutting their anchorage with the left fibrous trigon (Fig. 7(15, 16)), we have finished the dissection of the HVMB basal loop. At this point, it is important to notice that some fibers (i.e. belonging to the descendent segment) are sinking into the LV (Fig. 7(12, 13)), making the central fold of the HVMB. Trajectory of these fibers, while coming down towards the LV posterior wall, is pointing out an important cleavage plan at level of the interventricular septum (Fig. 7(13–15)). Namely, at the septal level, these fibers are crossing the ascendant segment fibers in a 90° angle. At this point, we are able to see this septal crossing from the LV side.

To continue with dissection, we should come back to the site of the previous posterior linear border of the RV cavity (Fig. 7(17)). By pure inspection from the RV side, we can clearly distinguish two muscular strata. The deeper belongs to previously described descendent segment and the more superficial belongs to the ascendant segment. A right-angle crossing of these fibers, as described before, is now also visible from the RV side. The cleavage plane between these

two strata (Fig. 7(18)) is the same one we described above, entering it from the LV side (Fig. 7(13–15, 20–21)). The top of the line (i.e. previous posterior linear border of the RV), defined by these two strata, ends on the aortic root at the point of its attachment to the right fibrous trigon. To separate described strata, going in between the vertical (more superficial, ascendant segment) and the horizontal (deeper, descendent segment) fibers, the first thing that we should do is to cutoff their anchorage to the right fibrous trigons (Fig. 7(18, 19)). Now we are able to proceed with the most delicate part of the dissection, denominated as 'dismounting of the aorta'.

Prior to any further description of the dissection method, it is important to emphasize one fact. The only firm aortic attachments to the LV are the fibrous trigons, upon which the aorta leans over the LV outflow tract. Apart from that, the aortic annulus, belonging to the right coronary cusp, provides the additional weak anchorage of the aorta to the septal portion of the LV. Thus, by cutting off these firm and weak attachments, it becomes possible to dismount the aorta from the LV (Fig. 7(15, 19–21)). By doing so, we are able to join two parts of the septal cleavage plan (Fig. 7(20)). In this manner, progressing along the predominant fiber path, we are able to detach the aorta with fibers belonging to the ascendant segment from the rest of the LV mass (Fig. 7(21, 22)). Following the same cleavage plan along the predominant helical fiber path (Fig. 7(22)), we are entering the LV cavity, with fingertips appearing behind the anterior papillary muscle, at the level of previously mentioned central fold of the HVMB (Fig. 7(23)). If we proceed until we become able to close the fist, our fingertips would appear




Fig. 8. The most important phases of the dissection procedure (bovine heart). Bottom: Torrent-Guasp's home-laboratory, where the HVMB concept was borne and where lots of people were able to learn Torrent-Guasp's dissections from the very source (photo by M.J. Kocica, 2002).

between anterior and posterior papillary muscles, the former being completely encircled by the hand.

Finally, we came to the aspect of the dissection when the HVMB is unraveled and finally ready to be stretched out to become a single straight myocardial band (Fig. 7(24)). A simple 90° rotation around the apex unravels the apical loop segments (Fig. 7(25)). Additional 180° rotation around the central fold unravels the basal and the apical loops of the HVMB (Fig. 7(26)). The HVMB of Torrent-Guasp now appears in its full extent and beauty, with pulmonary artery at one and the aorta at the opposite side (Fig. 7(27)).

Fig. 8 depicts the most important phases of the dissection procedure (see also Video 2—available only in online version of this article).

The elegance and astounding simplicity of this dissection is reflected in the capacity to easily reverse these unraveling steps, with ready re-establishment of the well-known three-dimensional ventricular architecture that existed prior to the beginning of dissection (Fig. 8 and Video 2).

The HVMB is divided in two loops, each of them comprising two segments (Fig. 9D). The central 180°-fold of the pulmonary artery defines two loops: the basal loop (from the root of the pulmonary artery to the beginning of the central fold—i.e. to the anterior papillary muscle) and the apical loop (from the beginning of the central fold to the root of the aorta) (Fig. 9B and D). Each of these two loops is further divided in two segments. The posterior interventricular sulcus topographically coincides with the posterior linear border of the RV cavity and divides the basal loop into two segments: the right segment—coinciding with the RV free wall and the left segment—coinciding with the LV free wall (Fig. 9B and D). The right segment also defines the outer (nonseptal) border of the tricuspid orifice and the left segment defines the outer (nonseptal) border of the mitral orifice. These borders are common targets in AV surgical annuloplasty procedures.

The apical loop is also divided in two segments. After the 180° twist (at the central fold of the HVMB), the descendant

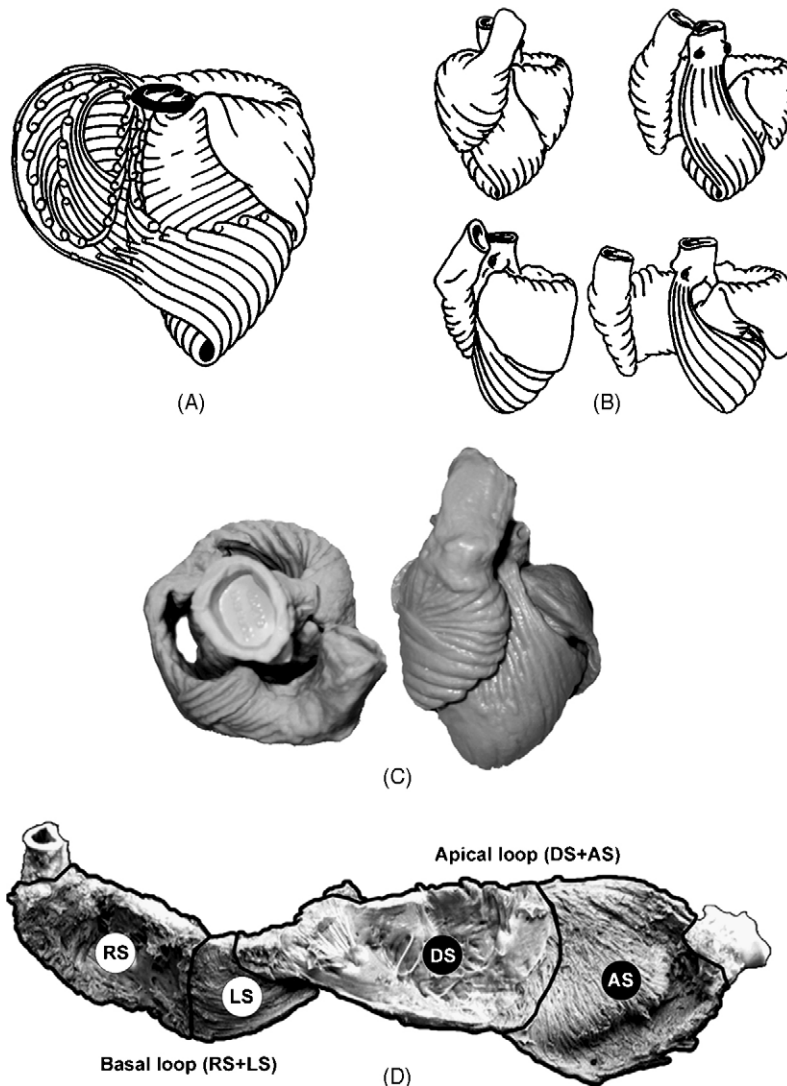


Fig. 9. (A) The last drawing made by Torrent-Guasp, illustrating a complex three-dimensional fiber architecture of the ventricular mass; (B) schematic presentation of the silicone-rubber mould of the HVMB (anterior and left-oblique view); (C) Torrent-Guasp's ©silicone-rubber mould of the HVMB; (D) segmental anatomy of the HVMB: RS, right segment; LS, left segment; DS, descendant segment; AS, ascendant segment.

fibers of the apical loop make a 90° turn around the apex becoming the ascendant fibers (Fig. 9B and D). Posterior papillary muscle (belonging to the descendant segment) demarcates the border between the descendant and the ascendant segments of the HVMB apical loop (Fig. 9A, B, and D).

These anatomical studies define the HVMB concept and provide a simple schema (Fig. 9A and B) that 'applies equally well to all the ventricular myocardial fibers, showing them joined together in a coherent common general architectural plan' [20]. The HVMB concept introduces an appropriate third dimension to the helical rope model (Figs. 5, 6, and 10C). To supplement the three-dimensional relations of the helical rope model, a silicon-rubber model and paper-strip model of the HVMB was developed. The first silicone-rubber mould of the HVMB (Fig. 9C) was produced in the early 1990s, from the matrices that Torrent-Guasp made using the unraveled bovine hearts. Made of special elastic material, this model

clearly reproduces all morphological features of the HVMB with high fidelity.

A paper-strip model (Fig. 10B and C) is easily constructed and permits ready comprehension of the triple helices comprising the ventricular mass [13,23]. Furthermore, this model depicts that global, three-dimensional ventricular architecture could be regarded as geometrically non-orientable surface, similar to triple-twisted Möbius strip (Fig. 10A–C) [51]. A Möbius strip is a one-sided surface that is constructed from a three-dimensional rectangle. Twisting this rectangle (i.e. the paper-strip) for 180° (one or more times) and attaching the ends to one another seems to eliminate one dimension of three-dimensional space. This possibility only exists in the curved space–time continuum revealed by Einstein. This purely geometrical analogy may apply to future research projects that deal with ventricular electrical and mechanical physiology.

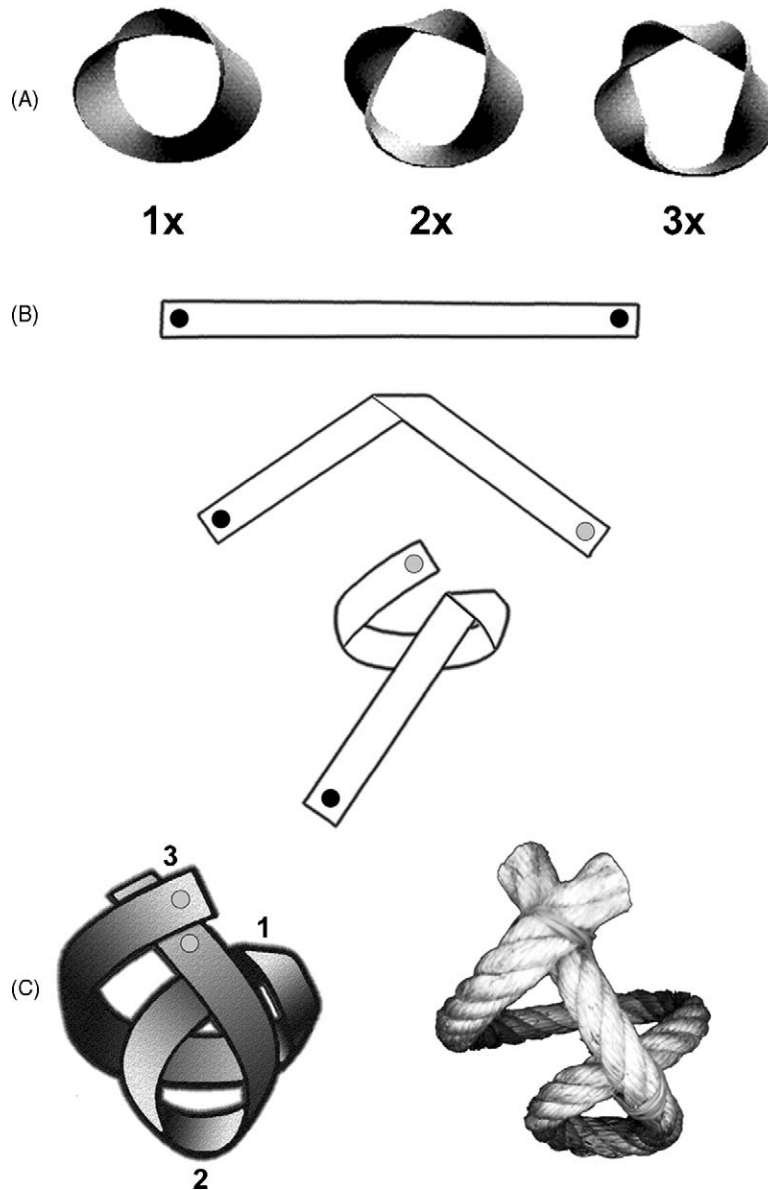


Fig. 10. Paper-strip model of the HVMB. (A) Single-, double- and triple-twisted Möbius strip [50]; (B) central fold of the HVMB demonstrated with paper-strip (black dot, visible side; gray dot, invisible side of the strip); (C) Paper-strip and helical rope models of the HVMB with annotated sites of three principal spirals within a complex helicoid: 1, central fold; 2, apical loop; 3, great arteries (i.e. 'truncus arteriosus' spiral septation).

3. Controversies

'Nature is simple, but scientists are complicated'. (Francisco Torrent-Guasp)

Although the basic anatomical investigations were completed by 1972, the first integral anatomical description of HVMB was published in 1980 [6]. The background of this concept was developed following more than 1000 meticulously prepared general or special (finite segments) dissections of the hearts of subjects that involved several different species. Since then, several basic principles and advances in understanding of HVMB form and function derived from Torrent-Guasp's continuous efforts to refine this concept, as well as from different studies done by others, were published in numerous papers [2,3,5,6,9,10,13,15,16,52–58]. More-

over, during the last decade, three successive, international, multidisciplinary symposia (Alicante 1995; Bethesda 2002 and Liverpool 2005) were organized to determine of the HVMB research principles which could be used as an infrastructure to further understand heart structure and function [22] relationships. The introduction of a new HVMB concept invariably introduces departures from currently accepted understandings and some of these issues will be addressed below.

3.1. Skeletal versus vasculature analogy?

Conceptually, the two contemporary and opposing schools about macroscopic structure of the ventricular myocardium are designated as 'HVMB' and 'Syncytial Mesh' strongholds, but they share substantial common ground

[7,12,17,18]. Neither concept questions the infinite anisotropy of the ventricular myocardium at microscopic level, whereby each myocyte is connected by intercalated discs and anchored to its neighbors by struts and weaves of supporting fibro-collagenous matrix (i.e. functional syncy-

tial mesh, resembling modified vascular musculature) [18]. Moreover, with the seminal work of Streeter [5] and subsequent reports on 'laminar sheet' organization of the myocardial fibers and surrounding matrix by Auckland group [8], 'functional syncytium mesh' (FSM) concept becomes the

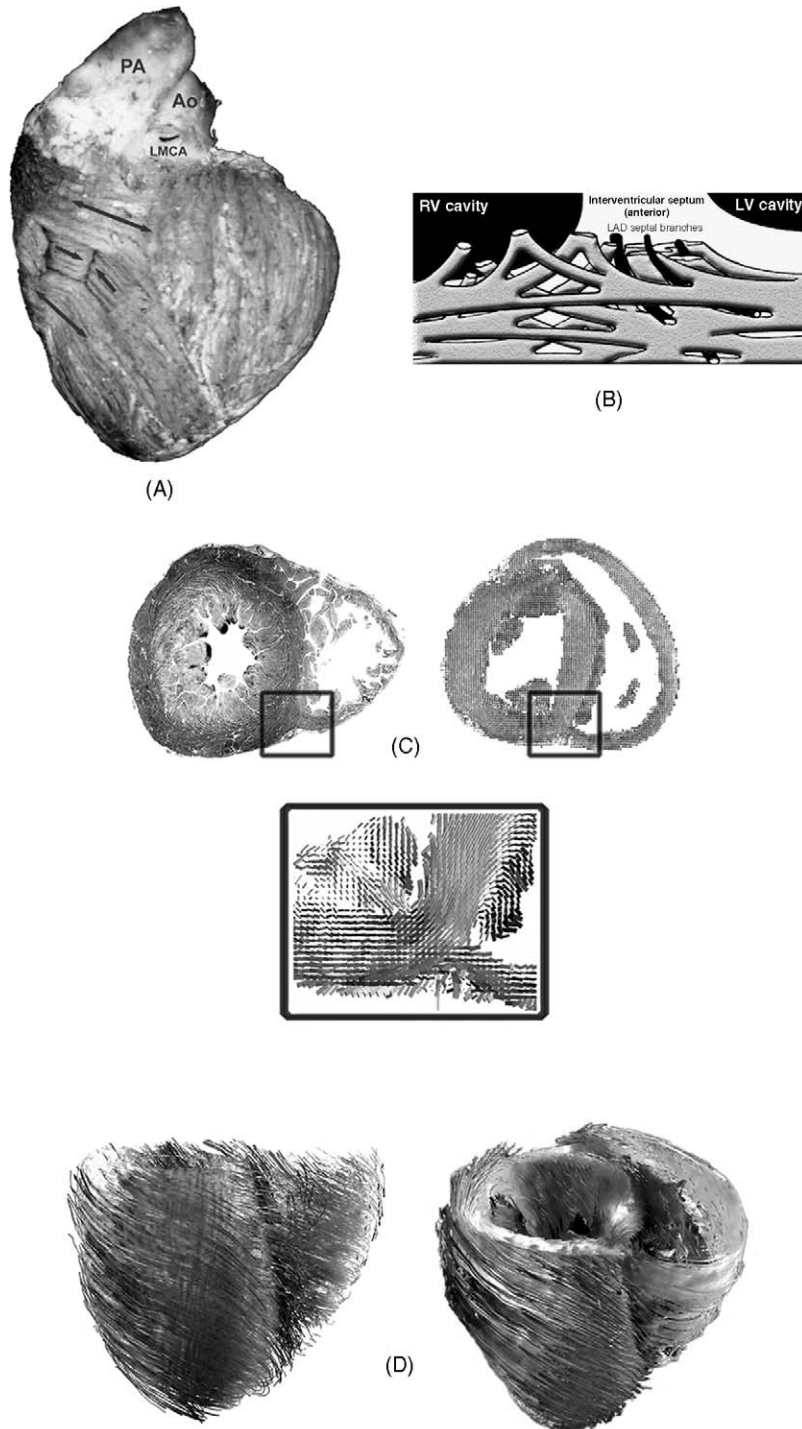


Fig. 11. Fiber disarray in the anterior and the posterior interventricular grooves. (A) Aberrant fibers (two-headed arrow lines) of the ascendant segment bridging the anterior interventricular sulcus (bovine heart). Single-headed arrow lines depict the opposite directions and independent intra-septal sinking of the anterior recurrent fibers (right) and the rest of the ascendant segment fibers (left). PA, pulmonary artery; Ao, aorta; LMCA, left main coronary artery. (B) Cartoon depicting anterior interventricular fiber disarray. (C) Histological and diffusion tensor MRI glyph-based visualization of the posterior interventricular fiber disarray. (D) Reconstruction of the posterior interventricular fibers using moving least squares fiber tracing algorithm (see also Video 1—available only in online version of this article). (C and D) Modified and reproduced with kind permission from Leonid Zhukov, Department of Computer Science, California Institute of Technology.)

essential histological prerequisite for proper understanding of local (but still) microscopic anisotropy within arbitrary chosen tissue-blocks (i.e. finite elements of the ventricular mass) [18].

However, can we resolve the problem of global, macroscopic myocardial anisotropy, applying purely (two- or even three-dimensional) histological analogy? Alternatively, can

we simply apply a higher, 'tissue-block logic', on the entire ventricular mass? The heart is simply 'greater than the sum of its constitutive parts' [58]. Evidently, in spite of considerable efforts [25,37,59], not any of these structural approaches alone could provide global three-dimensional model, which could fully explain cardiac function and its efficiency from the point of view of vectors of forces, generated during

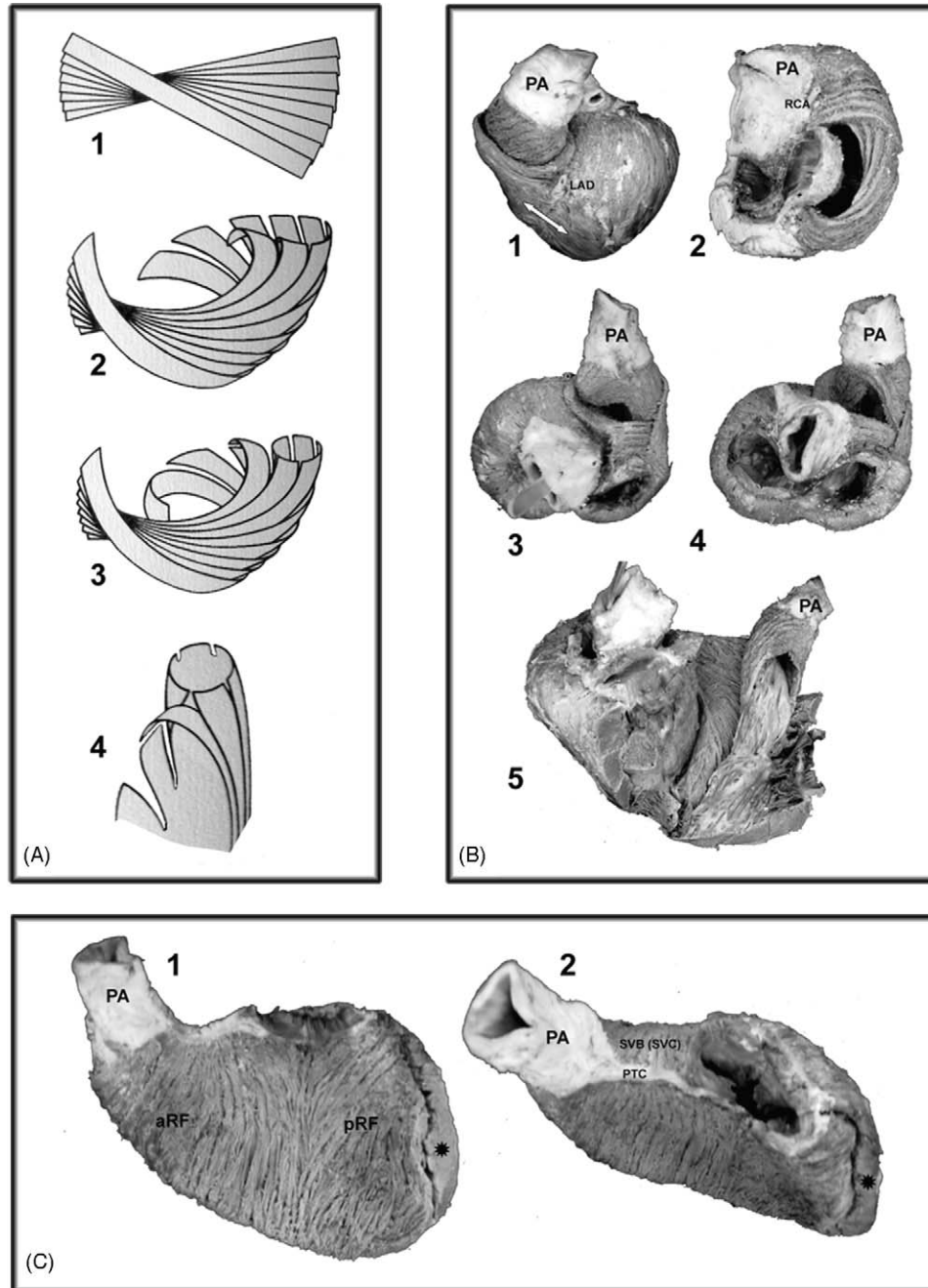


Fig. 12. HVMB concept of the right ventricular architectural design. (A) 'Japanese-fan' model of the right ventricle. (B) Special dissections of the right ventricle (bovine heart) depicting the fiber architecture correspondent with 'Japanese-fan' model. Two-headed arrow line (white) depicts the aberrant fibers bridging the anterior interventricular sulcus. PA, pulmonary artery; LAD, left anterior descending (artery); RCA, right coronary artery. (C) The right ventricle separated from the rest of the ventricular mass (septal and superior view). Black asterisk indicates the site of sharp incision over the proprietary right ventricular free wall fibers, passing in greater extent over the posterior interventricular sulcus to the posterior free wall of the left ventricle (see the explanation in the text). arf, anterior recurrent fibers; prf, posterior recurrent fibers; SVB (SVC), supra-ventricular bridge (crest).

dynamic interaction between the elastic and contractile elements.

The ultimate net result of the complicated myocardial fiber arrangement is to translate uniaxial sarcomere shortening into three-dimensional deformation of the ventricular cavity [59–61]. It is a well-known fact that myocardial architecture creates multiple inhomogeneities of electrical and mechanical loads at the cellular level, that cause cardiac function to be ‘stochastic in nature’. At a macroscopic level, however, these stochastic events

become averaged and appear consistent with a continuous medium [29,60–65]. As we emphasized earlier, Torrent-Guasp’s blunt anatomical dissections, following predominant fiber direction, shall reveal unique functional (i.e. vectorial) but not any eclectic (i.e. discrete) anatomical planes within ventricular mass. This arrangement defines the global, rule-based assignment that exists, along which the majority of fibers lie in the optimal direction, permitting them to orderly perform their function as a continuous medium.

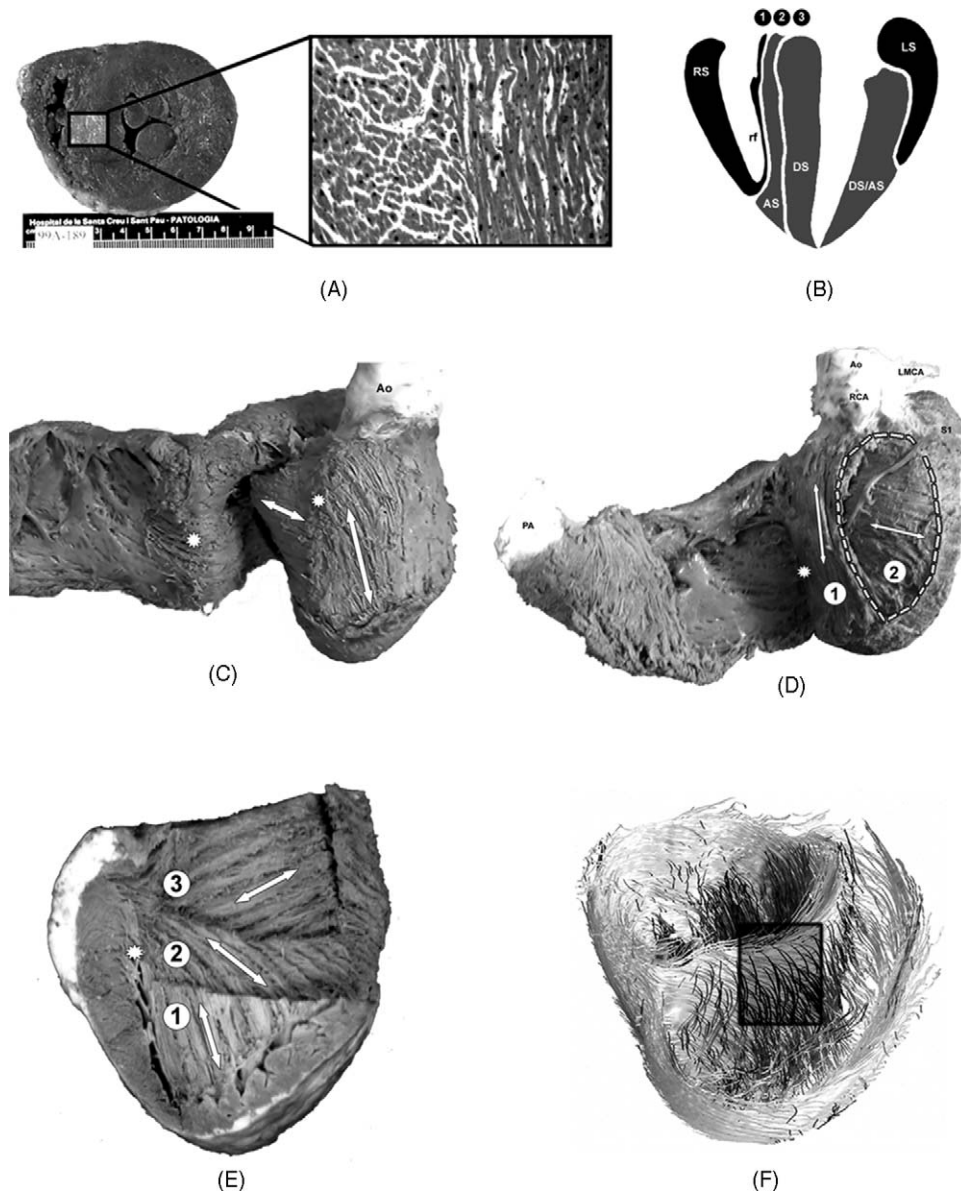


Fig. 13. Interventricular septum. (A) Histological evidence (human heart) of septal fiber crossing illustrating the sharp border between two different principal fiber directions. (B) Cartoon of the cleavage plans produced by following principal fiber direction (longitudinal section) depicting the fibers participating in septal formation. 1, Recurrent fibers (rf) (anterior and posterior); 2, ascendant segment fibers (AS); 3, descendant segment fibers (DS); RS, right segment; LS, left segment; DS/AS, descendent to ascendant segment transition. (C) Septal disarray (crossing) demonstrated at the level of the posterior linear border of the right ventricle (white asterisks). (D) Septal crossing at the level of the anterior interventricular sulcus. Dotted area depicts the zone of careful fiber peeling-off (no cleavage plans produced) until the first septal branch (S1) of the left anterior descending artery (LAD) appeared between 1 and 2 (numbers correspond with legend (B)). (E) Special dissection of the interventricular septum (bovine heart) with arrows showing three principal fiber directions (numbers correspond with legend (B)). (F) Reconstruction of the septal fibers using moving least squares fiber tracing algorithm emphasizing anterior and posterior recurrent fibers of the right ventricle (rectangle). ((A) By the courtesy of Francesc Carreras-Costa and Patho-histological department, Hospital Sant Pau, Barcelona, Spain; (F) Modified and reproduced with kind permission from Leonid Zhukov, Department of Computer Science, California Institute of Technology.)

Therefore, while the term ‘myocardial fibers’ reflects ‘a convenient description rather than anatomical entity’ [7,18,34], this concept is interpreted to reflect the meaningful reason for structural hierarchy that performs function. Our insisting on ‘functional’ instead of ‘anatomical’ personality of the ventricular fibers is based upon a ‘principal fiber direction’, a term that implies that no search is made for discrete ‘bundle-like’ anatomical entity because ‘principal fiber direction’ definitively does not comply with this concept. Nor is there denial that there is anatomical existence and functional significance of the ‘nonprincipal’ three-dimensional components (containing both myocardial and interstitial elements) that are destroyed within ventricular mass as ‘principal fiber direction’ is developed.

A commonly used argument in erroneous comparisons of the HVMB with skeletal muscle model was its ‘discrete origin, at the aortic outflow, and an insertion at the subpulmonary infundibulum’ [18]. This anatomical language enhances a false similarity of the HVMB and skeletal muscle (e.g. biceps brachii). Under no circumstances is the attachment of the entire ventricular mass, which extends from the pulmonary artery on the one side and to the aorta on the other, considered to perform its ‘skeletal-muscle-like-contraction’.

3.2. The interventricular sulci

Glisson, in 1641, compared the difference between ‘mangling’ and ‘mental’ dissections and lauded the mental capacity [66]. This concept was followed because there was not a place where the ‘systematically destroy the continuum of the bordering fibers’ [17,18,27] was done without recognizing their existence and significance while the predominant fiber orientation was defined. However, ‘predominant’ does not mean ‘exclusive’, so that certain areas within ventricular myocardial mass exhibit prominent fiber disarray (e.g. along the boundaries of the interventricular septum adjacent to the LV and RV free walls). However, specialized dissections showed that certain order in fiber arrangement exists even in these regions.

Thus, at the early stages of HVMB dissection, we cut off the ‘aberrant fibers’ that belong to the ascendant segment and traversing the anterior interventricular sulcus, end on the RV free wall and supraventricular crest (Fig. 11).

The term ‘aberrant’ is to define a smaller part of the LV ascendant segment fibers that significantly depart from the predominant direction of other fibers comprising this segment, but this term is not used to downgrade their importance. These fibers bridge the sulcus that separates two ventricles and may ensure their coordinated and synchronized functions [28]. These fibers have clinical significance because they pass over the left anterior descending artery (LAD) to create an intramyocardial LAD vessel. Nevertheless, their division is essential at the beginning of the HVMB dissection to enter the cleavage plan separating two ventricles, defined by the predominant orientation of the LV ascendant segment fibers and RV anterior recurrent fibers (Figs. 11A and B, and 12C). After this interruption, it becomes clear that the majority of ascendant segment fibers actually sink toward anterior interventricular septum. The situation at the posterior interventricular sulcus is quite different. The majority of proprietary RV free wall fibers are passing over the posterior interventricular sulcus to the posterior free wall of the LV, while their smaller part (i.e. posterior recurrent fibers) departs and sinks toward the posterior interventricular septum (Figs. 11C and D, and 12C). Thus, in order to enter the cleavage plan which completes the dissection of the HVMB basal loop, we intentionally cut through this tiny layer of the posterior recurrent fibers in the posterior linear border of the RV (Figs. 7(7–9), 11C and D, 12C, and 13C).

3.3. The interventricular septum

The interventricular septum displays fiber disarray at the boundaries of LV and RV free walls and contains an intriguing structure that may be freshly examined by the HVMB dissection. These dissections contradict the concept that the interventricular septum belongs to the LV, since both ventricles participate in its formation and the ascending and descending segments provide the origin and significance of septal fiber crossing as well as define the origin of the echocardiographic ‘bright line’ that separates the septum into left and right sides [67]. We suspect the overlap of the crossing of descending and ascending segments creates this ‘bright line’, a necessary border during the dissection. This is a connective tissue true space between ascending and

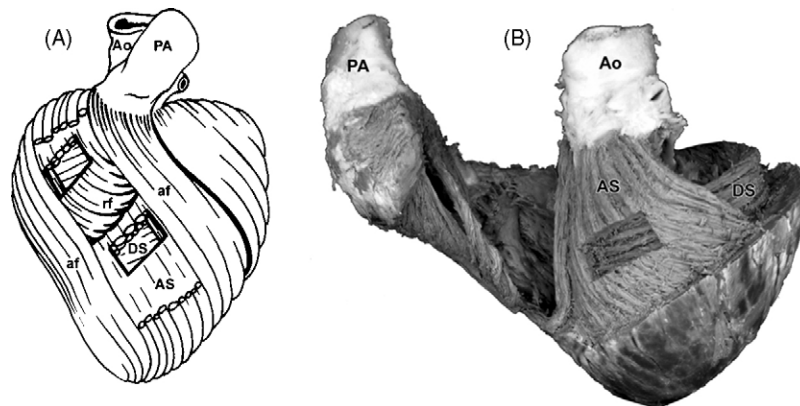


Fig. 14. Cartoon (A) and the anatomical specimen (B, bovine heart) illustrating the right and the left ventricular fiber architecture, as relevant for proper understanding of their relations at the anterior interventricular sulcus and the septum. DS, descendent segment; AS, ascendant segment; af, aberrant fibers; rf, recurrent fibers; PA, pulmonary artery; Ao, aorta.

descending segments and this belief may contradict the major assumption that this dissection 'might have disrupted the syncytial arrangement of the myofibres by creating a cleavage in the septum causing an artificially bilayered structure' [67].

Simple histological evidence of septal fiber crossing (Fig. 13A) illustrates the sharp border between two different principal fiber directions, which is not artifact but the reality. This histological fact was verified (Fig. 13C and D) at the level of posterior linear border of the RV and anterior interventricular sulcus by careful fiber peeling off, without producing any cleavage plan. Special dissections (of the RV and the interventricular septum) allowed us to conclude that both ventricles participate in the formation of the interventricular septum. The RV contributes with its anterior and

posterior recurrent fibers (Figs. 12A and C, 13B and C–F, and 14). These tiny, superficial fibers (looking from the RV side) have almost vertical direction (Fig. 13B, D, E and F). Recurrent fibers are laying over the ascendant segment fibers, which (after sinking into the anterior interventricular sulcus—Fig. 11A) run slightly obliquely and upward toward the root of the aorta (Figs. 13B–F and 14). Moreover, the first septal branch of the left anterior descending artery (which has to be preserved in Ross operation) runs exactly between these septal layers (Fig. 13D) with slightly different fiber orientations (the site of the first septal branch entrance is evident on Fig. 11A and B).

Finally, the third principal fiber direction within the interventricular septum belongs to the descendant segment (Figs. 13B, D, E and F, and 14). The orientation of these fibers

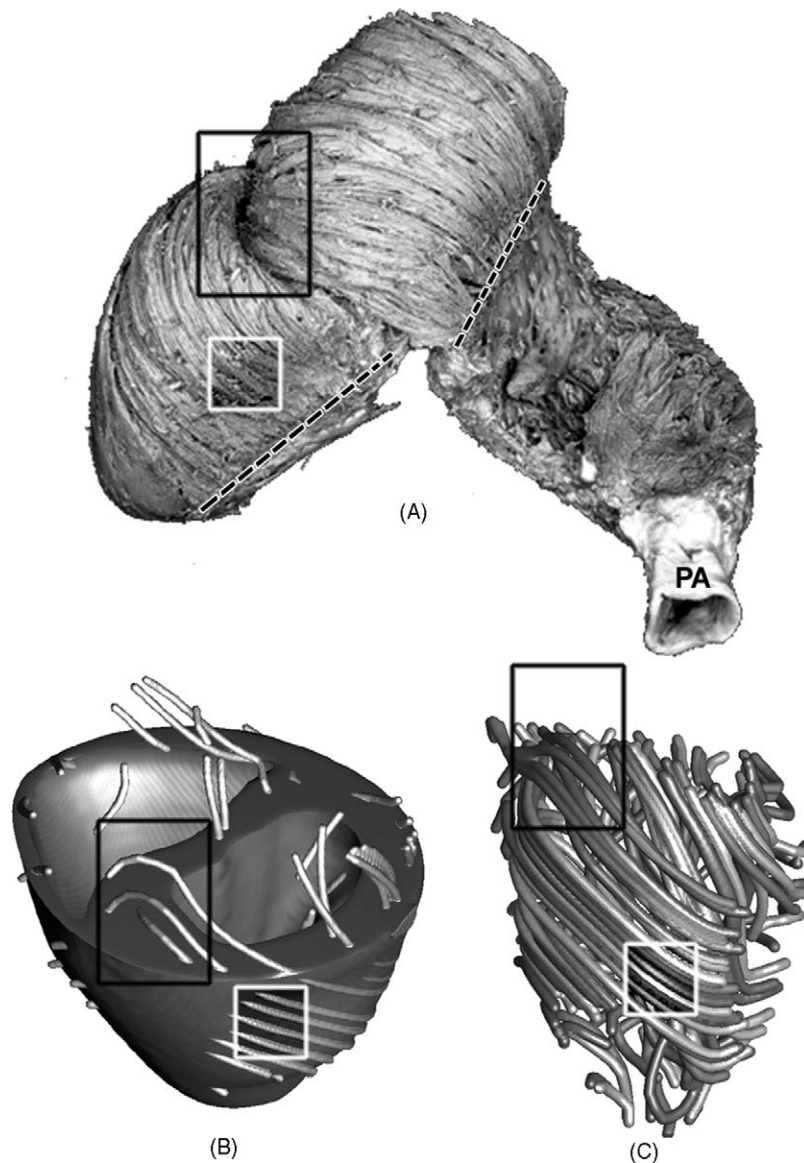


Fig. 15. Central fold of the HVMB. (A) Anatomical specimen (bovine heart) demonstrating 180° spiral turn of the basal loop (black rectangle). Dotted line depicts the posterior linear border of the right ventricle (i.e. the borderline between right and left segments of the basal loop). White rectangle emphasizes the principal fiber direction at the level of smooth ascendant-to-descendant segment transition. (B and C) Constructive volume geometry representations of corresponding areas (black and white rectangles) obtained from rabbit heart. (Modified and reproduced with kind permission from Aron V. Holden, School of Biomedical Sciences, University of Leeds and Min Chen, Department of Computer Science, University of Wales Swansea.)

differs markedly from the adjacent, ascendant segment fibers and becomes the anatomical substrate for the 90° septal fiber crossing (Fig. 13A). The functional significance of this septal fiber organization has to be subsequently examined.

3.4. Central fold of the HVMB

The HVMB dissection concurs with FSM concept proponents, regarding the ubiquitous existence of multiple side-branching within ventricular mass (including so-called 'intruding' branches) on the microscopic level [17,18] and also agree that 'cardiac muscle fibers are systematically aligned' on the macroscopic level [35]. The central fold of the HVMB is probably the most obvious reason to study cardiac structure and function through additive synergism instead of competitive antagonism.

The central fold of the HVMB (Fig. 15) is not a discrete anatomical entity but simply the term describing the region where the subepicardial fibers of the left segment of the basal loop make a 180° turn and become the subendocardial fibers of descending segment of the apical loop. This three-dimensional fold is clearly visible as 180° twist in unraveled HVMB (Figs. 8 and 9D) and in paper-strip models of the HVMB (Fig. 10B and C). The basal loop of the HVMB contains predominantly horizontal fiber directions (in two-dimensions) that surround and fully embrace the ventricular bases. The existence of the central fold preserves the continuity of these loops within the ventricular mass as well as the longitudinal axial continuity of adjacent segments in the unfolded band. When wrapped, a spiral is formed from fibers with pronouncedly different fiber orientations in three-dimensional space.

3.5. The apical loop of the HVMB

The apical loop of the HVMB is another part of the ventricular mass with pronounced difference in predominant fiber orientation, since descendant segment fibers and the ascendant segment fibers cross each other at a 90° angle around the apex (Fig. 16). This spiral turn at the apex mirrors

the central fold of the HVMB, thereby preserving the longitudinal axial continuity of these two segments of the ventricular mass in three-dimensional space as the heart is refolded. The apex of this 'minor spiral' was previously called the 'vortex cordis' [19].

4. Concluding remarks

'Sol Incit Omnibus' ('The Sun Shines for Everybody'—Francisco Torrent-Guasp's favorite Latin proverb)

Within the ventricular mass, size, shape, connections and orientation in a three-dimensional space of every single constituent determine its functional behavior. This kind of spatial dependence allows the ventricular myocardial mass to be considered as the source of interdependent vectorial forces (i.e. electrical and mechanical), being generated on different length and time scales (Fig. 17D). The ultimate net result of these vectorial forces is to translate uniaxial sarcomere shortening into efficient three-dimensional deformation of the ventricular cavity [43–45,60–65]. The complex architecture of the ventricular mass creates multiple inhomogeneities of electrical and mechanical loads at the cellular and the microscopic tissue level, that cause cardiac function to be 'stochastic in nature'. However, at macroscopic (i.e. organ) level, these stochastic events become average and appear consistent with a continuous medium [29–39]. This dialectic coexistence of complexity and simplicity, discreteness and continuity suggests the existence of certain rule-based assignment, which 'may be applied equally well to all the ventricular myocardial fibers' [20], enabling the ventricular myocardial mass to assemble abundant, dynamic, stochastic vectorial forces and produce apparently smooth, averaged, continuous, global response [29,39].

A single sarcomere, symbolizing the essence of heart's ability to work is viewed as the arbitrary 'quantum of continuity' that presents a fractal holding the secrets of complex interactions of form and function. Functional architecture of the sarcomere is applicable, on self-similarity basis, in all other scales, up to the complex geometry of the

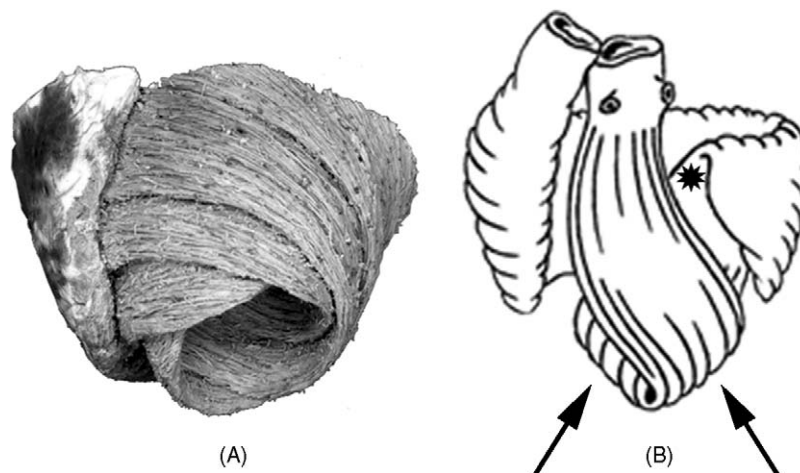


Fig. 16. The apical loop of the HVMB. Anatomical specimen (A) and cartoon (B) showing the 90° spiral turn of the descendant and the ascendant segment fibers around the apex (black arrows). Black asterisk indicates the site of HVMB central fold.

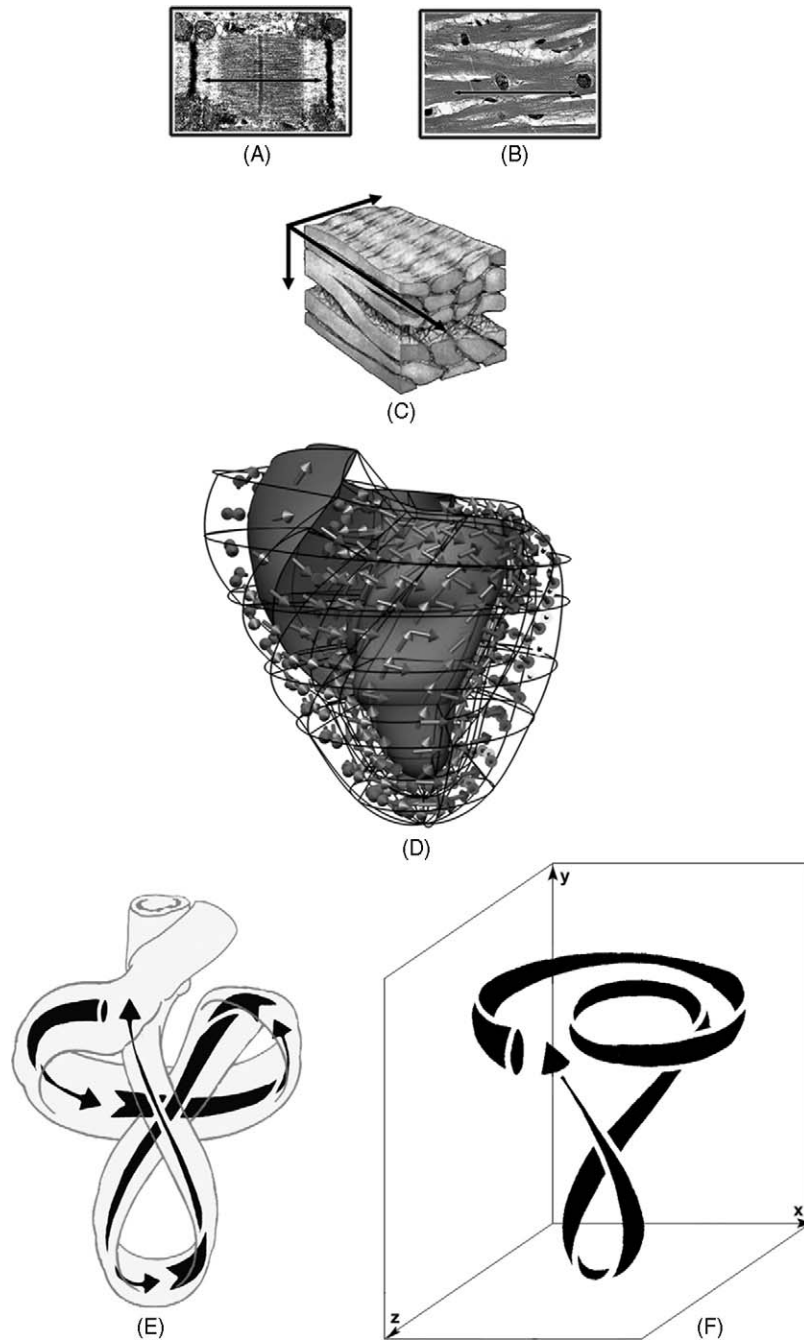


Fig. 17. (A) Photomicrograph of the single sarcomere with two-headed arrow line depicting the principle of structural and functional 'longitudinality'. (B and C) Principle of structural and functional 'longitudinality' on microscopic, cellular (B) and tissue block (C) levels. (D) A myriad of spatially and temporary dependent finite vectorial forces within ventricular mass. (E and F) HVMB as the spatial and temporal continuum integrating the tissue architecture (i.e. form) and net forces developed (i.e. function) within the ventricular mass (see the explanation in the text). ((D) Reproduced with kind permission from Peter J. Hunter, The University of Auckland, Bioengineering Institute.)

ventricular mass [68–70] (Fig. 17). Longitudinal sliding of the principal contractile proteins produces the changes in isoclinical sarcomere length. The orientation of force vector generated in this manner coincides with principal (i.e. longitudinal) axis of the sarcomeral contractile proteins. Its magnitude depends on complex interaction with Z-line proteins protecting the sarcomere from excessive length changes. The Z-line protein complexes are connected with

cellular membrane and subsequently with extracellular matrix and connective tissue, allowing the myocardial cell to exchange the 'information' about active and passive forces with neighboring cells. They are also connected with central 'computer of the cell' (i.e. the nucleus), translating these information into language of genetics, producing, by need, regulatory and structural proteins for short and long-term adjustments of stress and strain.

Therefore, three-dimensional functional architecture of the single sarcomere is adjusted to produce the active force along its principal longitudinal axis. The magnitude of this force is normally controlled by passive forces, developed by complex Z-line proteins, acting along different directions. Changing the magnitude of scope, we may find this fractal design of form and function preserved along increasing length scales. Thus, it has been proved that electrical impulses propagate more rapidly along rather than across the axis of the constituent fibers. In addition, the myocardial cells perform their functions by developing net tension along their longitudinal axes. Both facts do not exclude the existence and the importance of nonlongitudinal electrical and mechanical forces, just like the forces developed by principal contractile proteins are not the only forces developed within the sarcomere (Fig. 17A–C).

The FSM concept appropriately comprehends the integration of structure and function at microscopic length scales (Fig. 17A and B). Accordingly, the concept of 'laminar sheets' perfectly suits the understanding of myocardial form and function on a tissue block level, providing the finite element of the complex geometrical structure, which allows a mathematical modeling of the ventricles with acceptable degrees of freedom (Fig. 17C and D). However, the HVMB concept defines the principal, cumulative vectors, integrating the tissue architecture (i.e. form) and net forces developed (i.e. function) within the ventricular mass. Arbitrarily, there are four principal curvilinear vectors within ventricular myocardial mass, named after corresponding segments of the HVMB (Fig. 17E). According to their predominant orientation in three-dimensional space, they are grouped in two homologue pairs, named after corresponding loops of the HVMB. As an idealized approximation of reality, the HVMB concept integrates the ventricular form and function into a single helicoid three-dimensional vector (Fig. 17F). Appropriate mathematical formulation of this spatial and temporal continuum may lead to new constitutive equations of the ventricular myocardium, which might overcome the current limitations required to create a mathematical model of the heart [25,59].

The helical ventricular myocardial band of Torrent-Guasp conveys an important message (i.e. 'Sol Incit Omnibus') [71]. The architecture of this marvelous organ is 'big enough' for all of us—'FSM, laminar-sheet and HVMB people'. Kohl, Noble, Winslow and Hunter have nicely formulated this message, paraphrasing Hegel's dialectics: 'The logic of life will neither be recognized without precise understanding of the manifold of components that give rise to biological function, nor without a clear conception of the dynamic interactions between individual components on every level of functional integration. Likewise, the logic of life lies exclusively neither in the most incredible detail, nor in the most sweeping synopsis. Neither integrationism, nor reductionism, is self-sufficient. Both are obligatory to our quest for knowledge' [25].

The fundamental question should be 'what do we really know about normal and diseased heart structure and function', rather than becoming boxed-in by prior conceptions. We cannot continue to develop new diagnoses and therapies for heart diseases, without serious scientific consensus on these fundamental questions? That goal shall

be helped by further understanding of the helical ventricular myocardial band of Torrent-Guasp [22].

Acknowledgements

The authors would like to acknowledge the contribution of the following individuals: Donald N. Ross (London, United Kingdom); Masashi Komeda (Kyoto University Graduate School of Medicine, Department of Cardiovascular Surgery, Kyoto, Japan); Juan Cosin Aguilar (Cardiocirculatory Unit, Investigation Centre, University Hospital La Fe, Valencia, Spain); Albert Flotats (Department of Nuclear Medicine, Hospital Sant Pau, Barcelona, Spain); Fabio B. Jatene (University of Sao Paulo Medical School, Sao Paulo, Brazil); Jose Dario Frota Filho (Sao Francisco Hospital at Santa Casa de Porto Alegre, Porto Alegre, Brazil).

The authors would like to express their special gratitude to the family Torrent-Guasp and the Foundation 'Francisco Torrent-Guasp' for their kind permission to use the original graphic and video material in this article.

The authors owe the warmest gratitude to Gerald D. Buckberg (Option on Bioengineering at California Institute of Technology, and Division of Cardiothoracic Surgery, David Geffen School of Medicine at UCLA) for his patience, valuable editorial comments and revisions.

The authors also express our gratitude to Peter Hunter and Ian Le Grice (The University of Auckland, Bioengineering Institute); Leonid Zhukov (Department of Computer Science, California Institute of Technology); Arun V. Holden (School of Biomedical Sciences, University of Leeds) and Min Chen (Department of Computer Science, University of Wales Swansea) for their kind permission to reproduce and modify their original graphic and video material. Special thanks to Ms Christine Vertosick (Assistant to Gerald D. Buckberg) for her kind cooperation.

References

- [1] Kardel T. Steno on muscles: introduction, texts, translations. *Trans Am Phylos Soc* 1994;84(1):58–75.
- [2] Torrent-Guasp F, Ciclo Cardíaco El. Consideraciones críticas sobre la interpretación clásica y nuevas ideas sobre el mismo Madrid: Diana; 1954. p. 13–141.
- [3] Torrent-Guasp F. Anatomía funcional del corazón Madrid: Paz Montalvo; 1957. p. 62–8.
- [4] Robb JS. Comparative basic cardiology London: Grune and Stratton; 1965 p. 186–222.
- [5] Streeter Jr DD. Gross morphology and fiber geometry of the heart. In: Berne RM, Sperelakis N, editors. Handbook of physiology: section 2. The heart (American Physiology Society), vol. 1. Baltimore: Williams and Wilkins; 1979. p. 61–112.
- [6] Torrent-Guasp F. La estructuración macroscópica del miocardio ventricular. *Rev Esp Cardiol* 1980;33(3):265–87.
- [7] Greenbaum RA, Ho SY, Gibson DG, Becker AE, Anderson RH. Left ventricular fibre architecture in man. *Br Heart J* 1981;45:248–63.
- [8] LeGrice IJ, Smaill BH, Chai LZ, Edgar SG, Gavin JB, Hunter PJ. Laminar structure of the heart: ventricular myocyte arrangement and connective tissue architecture in the dog. *Am J Physiol* 1995;269(38):H571–82.
- [9] Ingels NB. Myocardial fiber architecture and left ventricular function. *Technol Health Care* 1997;5:45–52.
- [10] Scollan DF, Holmes A, Winslow R, Forder J. Histological validation of myocardial microstructure obtained from diffusion tensor magnetic resonance imaging. *Am J Physiol* 1998;275(44):H2308–1.
- [11] Spotnitz HM. Macro design, structure and mechanics of the left ventricle. *J Thorac Cardiovasc Surg* 2000;119:1053–77.

- [12] Jouk PS, Usson Y, Michalowicz G, Grossi L. Three-dimensional cartography of the pattern of the myofibres in the second trimester fetal human heart. *Anat Embryol* 2000;202:103–18.
- [13] Buckberg GD. Basic science review: the helix and the heart. *J Thorac Cardiovasc Surg* 2002;124:863–83.
- [14] Hildebrand R. Redensarten von der Würde eines Organs: Das Herz, ein Muskel. *Ann Anat* 2004;186:1–12.
- [15] Torrent-Guasp F, Kocica MJ, Corno A, Komeda M, Cox J, Flotats A, Ballester-Rodes M, Carreras-Costa F. Systolic ventricular filling. *Eur J Cardiothorac Surg* 2004;25(3):376–86.
- [16] Torrent-Guasp F, Kocica MJ, Corno AF, Komeda M, Carreras-Costa F, Flotats A, Cosin-Aguillar J, Wen H. Towards new understanding of the heart structure and function. *Eur J Cardiothorac Surg* 2005;27:191–201.
- [17] Lunkenheimer PP, Redmann K, Anderson RH. The architecture of the ventricular mass and its functional implications for organ preserving surgery. *Eur J Cardiothorac Surg* 2005;27:183–90.
- [18] Anderson RH, Ho SY, Redmann K, Sanchez-Quintana D, Lunkenheimer PP. The anatomical arrangement of the myocardial cells making up the ventricular mass. *Eur J Cardiothorac Surg* 2005;28:517–25.
- [19] Lower R. *Tractatus de corde: item de motu et colore sanguinis* London: Dawsons of Pall Mall; 1968.
- [20] Mall FP. On the muscular architecture of the ventricles of the human heart. *Am J Anat* 1911;11:211–66.
- [21] Pettigrew JB. On the arrangement of the muscular fibres in the ventricles of the vertebrate heart, with physiological remarks. *Phylos Trans* 1864;154:445–500.
- [22] Buckberg GD, Weisfeldt ML, Ballester M, Beyar R, Burkhoff D, Coghlan HC, Doyle M, Epstein ND, Gharib M, Ideker RE, Ingels NB, LeWinter MM, McCulloch AD, Pohost GM, Reinlib RJ, Sahn DJ, Spinale FG, Spotnitz HM, Sopko G, Torrent-Guasp F, Shapiro EP. Left ventricular form and function: scientific priorities and strategic planning for development of new views of disease. *Circulation* 2004;110:e333–6.
- [23] Buckberg GD. Architecture must document functional evidence to explain the living rhythm. *Eur J Cardiothorac Surg* 2005;27:202–9.
- [24] Hunter PJ, Borg TK. Integration from proteins to organs: the physiome project. *Nat Rev Mol Cell Biol* 2003;4(3):237–43.
- [25] Kohl P, Noble D, Winslow R, Hunter PJ. Computational modelling of biological systems: tools and visions. *Phil Trans R Soc Lond A* 1776;358:579–610.
- [26] von Segesser LK. The myocardial band: fiction or fact? *Eur J Cardiothorac Surg* 2005;27:181–2.
- [27] Criscione JC, Rodriguez F, Miller CD. The myocardial band: simplicity can be a weakness. *Eur J Cardiothorac Surg* 2005;28:363–4.
- [28] Yacoub MH. Two hearts that beat as one. *Circulation* 1995;92:156–7.
- [29] Spach MS, Heidlage JF. The stochastic nature of cardiac propagation at a microscopic level. Electrical description of myocardial architecture and its application to conduction. *Circ Res* 1995;76:366–80.
- [30] Sommer JR, Jennings RB. Ultrastructure of cardiac muscle. In: Fozzard HA, Haber E, Jennings RB, Katz AM, Morgan HE, editors. *The heart and cardiovascular system*. 2nd ed., New York: Raven Press, Ltd.; 1992. p. 3–50.
- [31] Hoyt RH, Cohen ML, Saffitz JE. Distribution and three-dimensional structure of intercellular junctions in canine myocardium. *Circ Res* 1989;64:563–74.
- [32] Spach MS, Heidlage JF, Barr RC, Dolber PC. Cell size and communication: role in structural and electrical development and remodeling of the heart. *Heart Rhythm* 2004;4:500–15.
- [33] Fernandez-Teran MA, Hurlé JM. Myocardial fiber architecture of the human heart ventricles. *Anat Rec* 1982;204(2):137–47.
- [34] Caulfield JB, Borg TK. The collagen network of the heart. *Lab Invest* 1979;40(3):364–72.
- [35] Niederer PF, Lunkenheimer PP, Cryer CW. On the significance of fiber branching in the human myocardium. *Biomech Model Mechanobiol* 2004;3:1–5.
- [36] Walker CA, Spinale FG. The structure and function of the cardiac myocyte: a review of fundamental concepts. *J Thorac Cardiovasc Surg* 1999;118:375–82.
- [37] Small BH, LeGrice IJ, Hooks DA, Pullan AJ, Caldwell BJ, Hunter PJ. Cardiac structure and electrical activation: models and measurement. *Proc Austral Physiol Pharm Soc* 2004;34:141–9.
- [38] LeGrice IJ, Takayama Y, Covell JW. Transverse shear along myocardial cleavage planes provides a mechanism for normal systolic wall thickening. *Circ Res* 1995;77:182–93.
- [39] Kevrekidis PG, Kevrekidis IG, Bishop AR, Titi ES. Continuum approach to discreteness. *Phys Rev E Stat Nonlin Soft Matter Phys* 2002;65:046613.
- [40] Sedmera D. Form follows function: developmental and physiological view on ventricular myocardial architecture. *Eur J Cardiothorac Surg* 2005;28:526–8.
- [41] Simoes-Costa MS, Vasconcelos M, Sampaio AC, Cravo RM, Linhares VL, Hochgreb T, Yan CY, Davidson B, Xavier-Neto J. The evolutionary origin of cardiac chambers. *Dev Biol* 2005;277(1):1–15.
- [42] Moorman AFM, Christoffels VM. Cardiac chamber formation: development, genes, and evolution. *Physiol Rev* 2003;83:1223–67.
- [43] Manasek FJ. Histogenesis of the embryonic myocardium. *Am J Cardiol* 1970;25:149–68.
- [44] Gregorio CC, Antin PB. To the heart of myofibril assembly. *Trends Cell Biol* 2000;10:355–62.
- [45] Taber LA. Mechanical aspects of cardiac development. *Prog Biophys Mol Biol* 1998;69:237–55.
- [46] Sedmera D, Pexieder T, Hu N, Clark EB. Developmental changes in the myocardial architecture of the chick. *Anat Rec* 1997;248:421–32.
- [47] Sedmera D, Pexieder T, Vuillemin M, Thompson RP, Anderson RH. Developmental patterning of the myocardium. *Anat Rec* 2000;258:319–37.
- [48] Sedmera D, Pexieder T, Hu N, Clark EB. A quantitative study of the ventricular myoarchitecture in the stage 21–29 chick embryo following decreased loading. *Eur J Morphol* 1998;36(2):105–19.
- [49] Manner J. Cardiac looping in the chick embryo: a morphological review with special reference to terminological and biomechanical aspects of the looping process. *Anat Rec* 2000;259:248–62.
- [50] Buckberg GD. The structure and function of the helical heart and its buttress wrapping. II. Interface between unfolded myocardial band and evolution of primitive heart. *Semin Thorac Cardiovasc Surg* 2001;13(4):320–32.
- [51] Niamsup P. A note on the characteristics of Möbius transformations. *J Math Anal Appl* 2000;248:203–15.
- [52] Scollan DF, Holmes A, Winslow R, Forder J. Histological validation of myocardial microstructure obtained from diffusion tensor magnetic resonance imaging. *Am J Physiol (Heart Circ Physiol)* 1998;275:H2308–1.
- [53] Masood S, Yang GZ, Pennell DJ, Firmin DN. Investigating intrinsic myocardial mechanics: the role of MR tagging, velocity phase mapping, and diffusion imaging. *J Magn Reson Imag* 2000;12:873–83.
- [54] Marino B, Corno AF. Spiral pattern: universe, normal heart, and complex congenital defects. *J Thorac Cardiovasc Surg* 2003;126(4):1225–6.
- [55] Arts T, Costa KD, Covell JW, McCulloch AD. Relating myocardial laminar architecture to shear strain and muscle fiber orientation. *Am J Physiol (Heart Circ Physiol)* 2001;280:H2222–9.
- [56] Castella M, Buckberg GD, Saleh S, Gharib M. Structure function interface with sequential shortening of basal and apical components of the myocardial band. *Eur J Cardiothorac Surg* 2005;27:980–7.
- [57] Ballester-Rodes M, Flotats A, Torrent-Guasp F, Ballester-Alomar M, Carreras F, Ferreira A, Narula J. Base-to-apex ventricular activation: Fourier studies in 29 normal individuals. *Eur J Nucl Med Mol Imag* 2005;32:1481–3.
- [58] Kresh JY, Armour JA. The heart as a self-regulating system: integration of homeodynamic mechanisms. *Technol Health Care* 1997;5:159–69.
- [59] Noble D. Modeling the heart. *Physiology* 2004;19:191–7.
- [60] Freeman GL, LeWinter MM, Engler RL, Covell JW. Relationship between myocardial fiber direction and segment shortening in the midwall of the canine left ventricle. *Circ Res* 1985;56:31–9.
- [61] Spotnitz HM. Macro design, structure and mechanics of the left ventricle. *J Thorac Cardiovasc Surg* 2000;119:1053–77.
- [62] Hexeberg E, Homans DC, Bache RJ. Interpretation of systolic wall thickening. Can thickening of a discrete layer reflect fibre performance? *Cardiovasc Res* 1995;29:16–21.
- [63] Sachse FB, Seemann G, Werner CD. Combining the electrical and mechanical functions of the heart. *Int J Biol* 2001;3(2):1–13.
- [64] Mashima S. Myocardial electrogenesis and the electrocardiogram. *Jpn Heart J* 1999;40:1–9.
- [65] Spach MS, Barr RC. Effects of cardiac microstructure on propagating electrical waveforms. *Circ Res* 2000;86:e23–8.
- [66] Cunningham A. The pen and the sword: recovering the disciplinary identity of physiology and anatomy before 1800 II: old anatomy—the sword. *Stud Hist Phil Biol Biomed Sci* 2003;34:51–76.
- [67] Boettler P, Claus P, Herbots L, McLaughlin M, D'hooge J, Bijmens B, Ho SY, Kececioglu D, Sutherland GR. New aspects of the ventricular septum and its function: an echocardiographic study. *Heart* 2005;91:1343–8.

- [68] Goldberger AL. Non-linear dynamics for clinicians: chaos theory, fractals, and complexity at the bedside. *Lancet* 1996;347:1312–4.
- [69] Goldberger AL, Amaral LAN, Glass L, Hausdorff JM, Ivanov PCH, Mark RG, Mietus JE, Moody GB, Peng C-K, Stanley HE. PhysioBank, physiotoolkit, and physionet: components of a new research resource for complex physiologic signals. *Circulation* 2000;101(23):e215–20.
- [70] Wagner CD, Persson PB. Chaos in the cardiovascular system: an update. *Cardiovasc Res* 1998;40:257–64.
- [71] Torrent-Guasp F, Kocica MJ, Corno AF, Carreras-Costa F. Sol incit omnibus. *Eur J Cardiothorac Surg* 2005;28:365–6.

Appendix A. Supplementary data

Supplementary data associated with this article can be found, in the online version, at [doi:10.1016/j.ejcts.2006.03.011](https://doi.org/10.1016/j.ejcts.2006.03.011).

The helical ventricular myocardial band: global, three-dimensional, functional architecture of the ventricular myocardium

Mladen J. Kocica, Antonio F. Corno, Francesc Carreras-Costa, Manel Ballester-Rodes, Mark C. Moghbel, Clotario N.C. Cueva, Vesna Lackovic, Vladimir I. Kanjuh and

Francisco Torrent-Guasp

Eur J Cardiothorac Surg 2006;29:21-40

DOI: 10.1016/j.ejcts.2006.03.011

This information is current as of July 28, 2009

Updated Information & Services	including high-resolution figures, can be found at: http://ejcts.ctsnetjournals.org/cgi/content/full/29/Suppl_1/S21
References	This article cites 65 articles, 30 of which you can access for free at: http://ejcts.ctsnetjournals.org/cgi/content/full/29/Suppl_1/S21#BIBL
Citations	This article has been cited by 3 HighWire-hosted articles: http://ejcts.ctsnetjournals.org/cgi/content/full/29/Suppl_1/S21#otherarticles
Subspecialty Collections	This article, along with others on similar topics, appears in the following collection(s): Cardiac - physiology http://ejcts.ctsnetjournals.org/cgi/collection/cardiac_physiology Cardiac - other http://ejcts.ctsnetjournals.org/cgi/collection/cardiac_other Myocardial protection http://ejcts.ctsnetjournals.org/cgi/collection/myocardial_protection
Permissions & Licensing	Information about reproducing this article in parts (figures, tables) or in its entirety can be found online at: http://ejcts.ctsnetjournals.org/misc/Permissions.shtml
Reprints	Information about ordering reprints can be found online: http://ejcts.ctsnetjournals.org/misc/reprints.shtml

EUROPEAN JOURNAL OF
**CARDIO-THORACIC
SURGERY**